

SHELDON FRIEL MEMORIAL LECTURE 2007

Myths and Legends in Orthodontics*

Frans P.G.M. van der Linden

Radboud University Nymegen, Netherlands

SUMMARY Opinions and procedures, which are incorrect or invalid but continue to exist, are discussed. Eight seldomly criticised subjects have been selected which are relevant for the theory and practice of orthodontics. First, the idea that all individuals have or can reach an occlusion with contact between all opposing teeth is commented upon. Second, interest and preferences of editors and referees in the acceptance of manuscripts is clarified and the neglecting of published information explained. Third, the reliability of conclusions drawn from lateral roentgenocephalograms is reviewed in regard of the accuracy of commonly used bony landmarks. Fourth, the interpretation of growth data concerning visual interpretation, error of the method and reliability of conclusions based on cephalometric data, is treated. Fifth, the need of lateral roentgenocephalograms and recently developed digital techniques for diagnostic purposes is evaluated. Sixth, the validity of facial orthopedics, and particularly its supposed contribution to the improvement of facial configuration and beauty is analysed. Seventh, the idea that the increase of mandibular intercanine width is the cause of the occurrence of mandibular incisor irregularities after alignment by treatment is challenged. Eight, the usefulness of traditional removable retainers as the Hawley and “wrap-around” appliance, is questioned and an approach and design, adapted to the change from banding to bonding of fixed appliances, is presented.

Introduction

In the past 50 years, the field of Orthodontics has changed markedly. On the one hand, theoretical and particularly clinical advancements have made treatment procedures more efficient and refined, facilitating the realisation of excellent results. On the other hand, concepts and procedures have been generally accepted, which are improper or useless. A critical view on a number of these aspects is presented.

Occlusion

A standard occlusion with all anterior and posterior opposing teeth in contact with each other is taken for granted in most textbooks and publications in dental and orthodontic journals. Orthodontic malocclusions are supposed to be treated to an ideal occlusion and vertical contacts in habitual occlusion subsequently maintained, albeit that minor changes in tooth position may occur later. However, this concept is not true. Many individuals have no vertical contact of the anterior teeth. A solid occlusion between all opposing posterior teeth often does not exist, however, less frequently.

Lack of vertical contact can be differentiated in open bites and nonocclusions. The change-over point is where the overlap gets lost. Whether or not an overlap exists in borderline situations is irrelevant for the therapy and further development (Moyers, 1988). Open bites and nonocclusions occur in all types of malocclusions, including coverbites

(Class II/2s and Class Is with symptoms of Class II/2) (Figure 1). They occur worldwide, and frequently in the Netherlands. A large Dutch epidemiologic study revealed that the mandibular incisors were not in contact with the maxillary incisors in 40% of the 2,273 examined individuals between 15 and 70 years of age. This was even more common in adolescents (between 15 and 20 years of age), among whom 59% of 525 examined individuals did not have anterior contact. For the posterior regions, the percentages for open bites and nonocclusions combined were 10% and 18% for the study group as a whole and adolescents, respectively. These data indicate that open bites and nonocclusions occur more often in adolescents than in adults (De Kanter, 1990; Frankenmolen, 1990). Based on these findings and information from other studies, it can be concluded that open bites and nonocclusions disappear spontaneously in about half of the children between 8 and 15 years of age, and in about one third of the adolescents (Goldstein and Stanton, 1936; Helm, 1970). In most of these cases, the tongue interposition plays a major role. The transition to another tongue position in the growing and maturing face is related to changes in size, relationships and behaviour of various structures and to an alteration of the genetically determined neuromuscular control of the tongue position at an older age.

Orthodontic correction of open bites and nonocclusions is often difficult and all over vertical contact cannot always

* This paper is published as submitted without being subject to refereeing or editorial correction. The article does not comply with the formatting of the *European Journal of Orthodontics*.

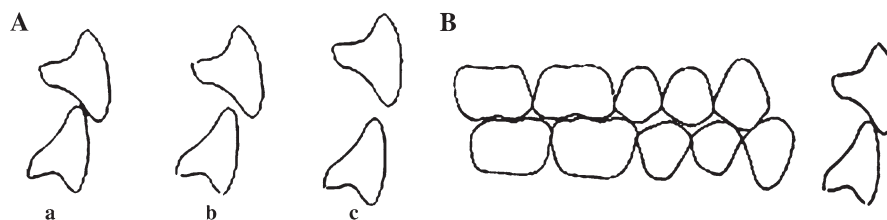


Figure 1 In a Class I situation, the incisors overlap each other with contact in the anterior region (Aa). In a nonocclusion, the anterior teeth overlap but do not contact each other; there is some space between them (Ab). Only when there is no overlapping, the term open bite is used (Ac). Open bites can occur also in the posterior regions, partially or completely. Sometimes, a nonocclusion is found between all teeth, combined or not with a local open bite (B).

be achieved. Furthermore, established vertical contacts can get lost, sooner or later. Open bites and nonocclusions can exist lifelong, as can be seen in a patient, which treatment was started by the author in 1957 and documented again 50 years later in 2007 (Figure 2).

Indeed, an occlusion in which all anterior and posterior opposing teeth are in contact with each other is not found in a substantial part of the population and cannot be achieved in all malocclusions treated orthodontically, even not with complementary orthognathic surgery. In quite a number of cases in which this goal could be achieved, some loss of vertical contact occurs later on (Figure 18).

In conclusion, the so called ideal standard occlusion as the exclusive norm, is a myth. Situations in which functional conditions prohibit reaching a full solid occlusion, or cause a partly return to lack of vertical contacts between opposing teeth after treatment, should be accepted as a reality.

Literature

The content of popular journals sold to the general public is mainly based on what the market wants. Professional journals accept and reject manuscripts partly based on what editors consider to be of interest for the subscribers, often supported by the opinion of referees. Publications which challenge common views are not so readily accepted, and particularly not recommendations for approaches which are an improvement but result in a reduction of the financial benefit for the provider. That applies especially to existing diagnostic techniques and newly introduced ones which seem to enhance the professional status of the practitioner, but provide information that can also be obtained with simpler means or is not needed anyhow. In addition, publications with remarks of that type are generally neglected and seldom referred to.

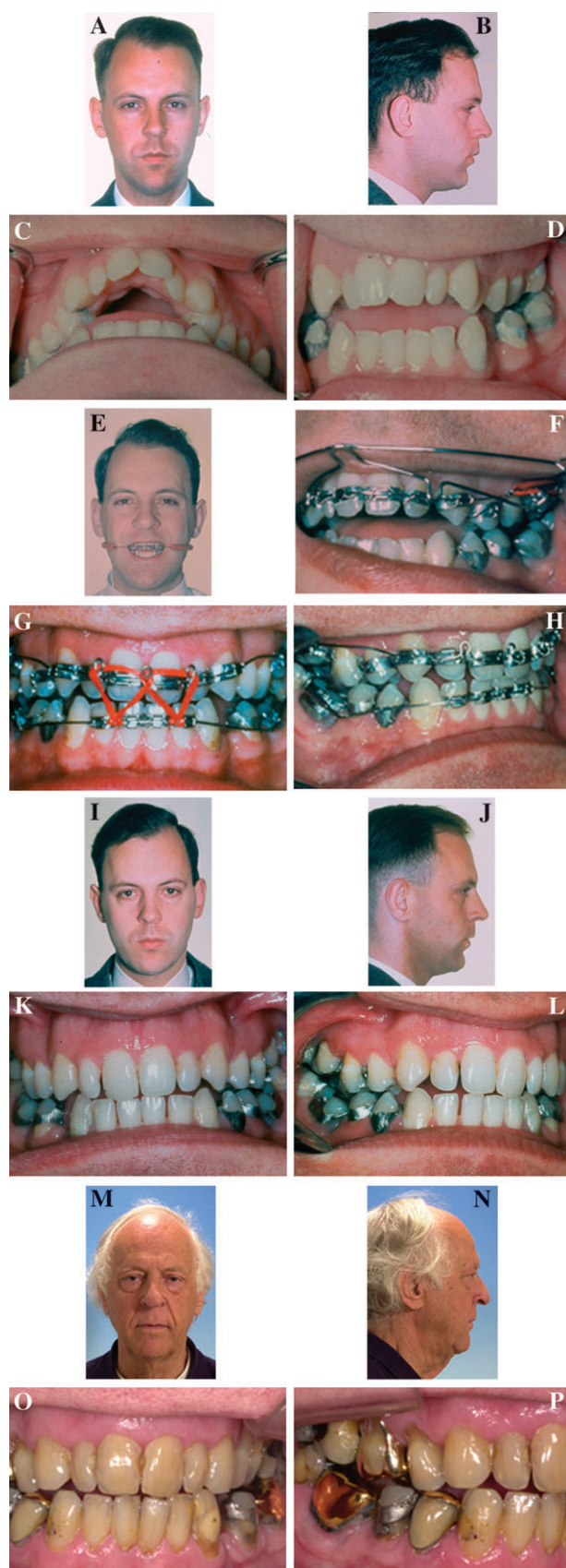Interest of editors varies and new editors may accept papers which their predecessors did not consider to be of interest to the readers. Besides, interests of readers vary over time. The author experienced that at the end of the sixties and early seventies of last century. In 1968 he submitted a manuscript with the title "The application of removable orthodontic appliances in multiband techniques" to the American Journal of Orthodontics. The manuscript was

rejected by the editor Pollock and subsequently submitted to the Angle Orthodontist, which editor Lewis published without any changes. One year later, the author submitted a research paper "The study of roentgenocephalometric bony landmarks" to the American Journal of Orthodontics. The editor Dewel, who recently had replaced Pollock, wrote back that he was only willing to publish that paper if first a manuscript was submitted on the use of removable appliances, which was done. In 1971, the cephalometric paper and the paper "The removable orthodontic appliance" appeared with a few months in between (Van der Linden, 1971¹; 1971²). Partly based on this type of experience, and the selection of editors and preferences and ideas of referees, the author concentrated on publishing in textbooks (Van der Linden and Duterloo, 1976; Van der Linden, 1983; 1986; Van der Linden and Boersma, 1987; Van der Linden, 1990; 1996; 1997; 2004).

In conclusion, what appears in professional journals is to some extent selected on subjective grounds. Authors are inclined to submit papers that meet the wishes of the journals in which they like them to be published. In addition, information that is not attractive for the readers is conveniently neglected.

Reality of Cephalometrics

It is amazing to realise that cephalometrics has been used in orthodontics for more than 50 years without much interest in its validity. The first paper on the accuracy of commonly used landmarks appeared in 1961 and was based on one skull only (Yen, 1961). The second paper on this topic was the one of the author mentioned in the previous paragraph (Van der Linden, 1971¹). Sixty four human skulls of various developmental stages were studied in detail to analyse if the commonly used landmarks coincided with the generally accepted definitions. It was found that a number of landmarks deviated from these definitions. This was the case for prosthion, infradentale, menton, gnathion and particularly for point A. Point A, introduced by Downs (Brodie, 1944), is supposed to be located at the curvature of the anterior edge of the bony ridge and was defined by him as "the deepest midline point on the premaxilla between the anterior nasal spine and prosthion". Björk (1947) defined point A as



“the deepest point on the contour of the alveolar projection between the spinal point and prosthion”. The observations on the 64 skulls did not confirm these definitions or ones presented by others (Krogman and Sassouni, 1957). On the lateral roentgencephalograms of all skulls, the anterior outline between the anterior nasal spine and prosthion was caused by parasagittal structures in the inferior region and by midline structures superiorly. Invariably, the outline of the alveolar bone labially from one or both central incisors composed the inferior part whereas the midline structure was more dorsal and not visible on the radiograph (Figure 3A). The shape and location of the bony ridge change with the development of the dentition and jaw growth. In addition, the distance from prosthion to anterior nasal spine, and the position and inclination of the central incisors affect the location of point A (Figure 3B). Besides, the anterior border of the maxilla is not represented by point A, but by the anterior surface of the labial lamella(e) covering the central incisor(s) at the region of the apex, where the more or less straight anterior outline changes over to the rounded contour. As a replacement for point A the author introduced point L. Point L is located at the anterior surface of the image of the labial lamella(e) at the region of the apex (apices). Point L is independent of the midline structure and is, by definition, located at the apical base region. The visibility of the bony landmarks is clearer on radiographs of dry skulls than of those of living persons. That applies particularly to the anterior region of the maxilla where the image of soft tissues can obscure bony details. If point L is not clearly visible on the lateral roentgenocephalogram, it can be located 1 mm in front of the apices (Figure 4A, Van der Linden, 1971¹).

Also the posterior nasal spine varies in anteroposterior position and is not representative for the posterior demarcation of the maxilla, but the dorsal boundaries of the maxillary tuberositas are (Figure 4B).

The influence of the position and inclination of the maxillary central incisors on the morphology of the anterior part of the maxilla shows up clearly when the crowns of these incisors become tipped palatally by excessive coverage of the lower lip as happens in Class II/2 situations and in other malocclusions with a high lower lip position (coverbites). The curvature gradually disappears when the apices move labially (Figures 5, 6).

In conclusion, the generally accepted definitions of cephalometric bony landmarks are not correct for a number of points. Furthermore, it is wrong to assume that point A is a good representation of the anterior boundary of the maxilla in the alveolar region and posterior nasal spine of the posterior boundary.

Figure 2 A patient of 26 years of age had a Class II/1 and a severe open bite (A-D). He was treated with cervical headgear, maxillary plate and twin wire appliance (E-H). At the end of treatment, at 28 years of age, he has a slight open bite in the anterior region and non-occlusions in the posterior regions (I-L). At 76 years after the start of treatment, an open bite and nonocclusions are still present (M-P).

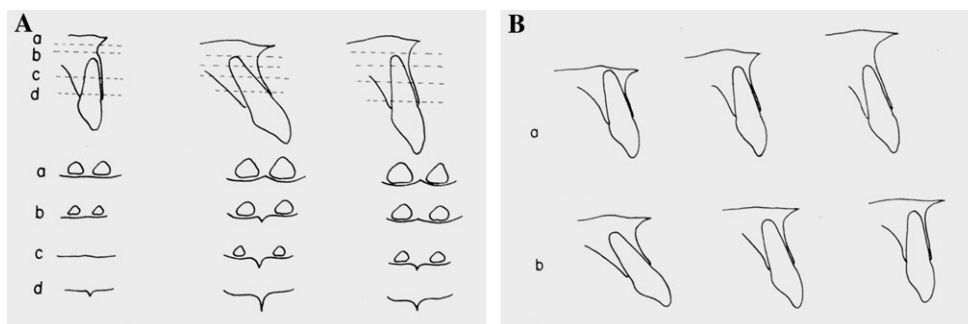


Figure 3 Variations in the morphology of the anterior maxillary region (A). The location of point A depends on the distance from prosthion to anterior nasal spine and the inclination of the incisors (B) (Van der Linden, 1971¹).

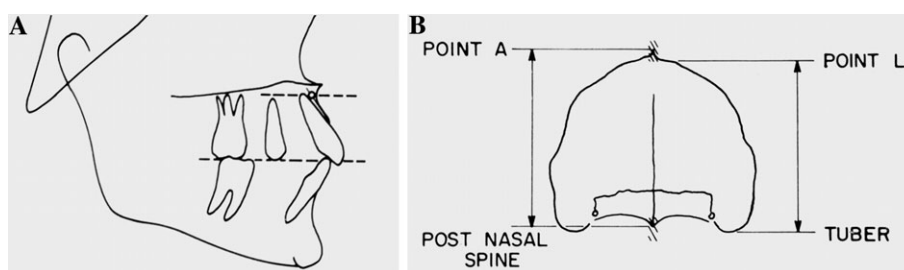


Figure 4 Point L is located at the anterior surface of the labial lamella(e) covering the central incisor(s) at the region of the completed root, where its more or less straight outline changes over to the rounding contour. In this the functional occlusal plane is used as a reference line (A). The locations of point A and posterior nasal spine vary in anteroposterior direction as a result of factors not essential in the determination of the anteroposterior dimension of the maxilla. These shortcomings are greatly eliminated when point L and the dorsal boundaries of the maxillary tuberositas are used for this purpose (B) (Van der Linden, 1971¹).

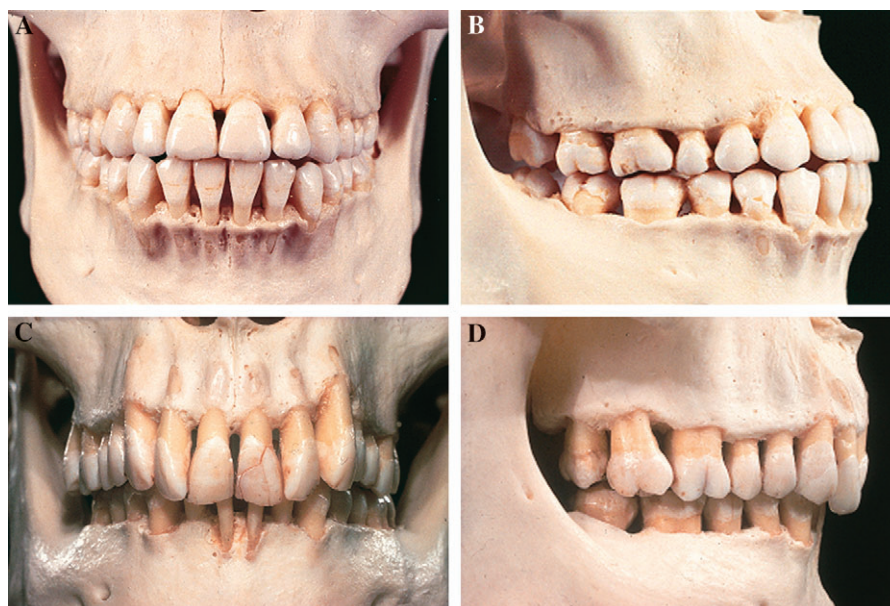


Figure 5 An adult human skull, with a normal inclination of maxillary incisors and anterior contour of the maxillary (A,B). Another skull with excessive palatal tipping of the maxillary incisors with associated deformation of the anterior contour (C,D).

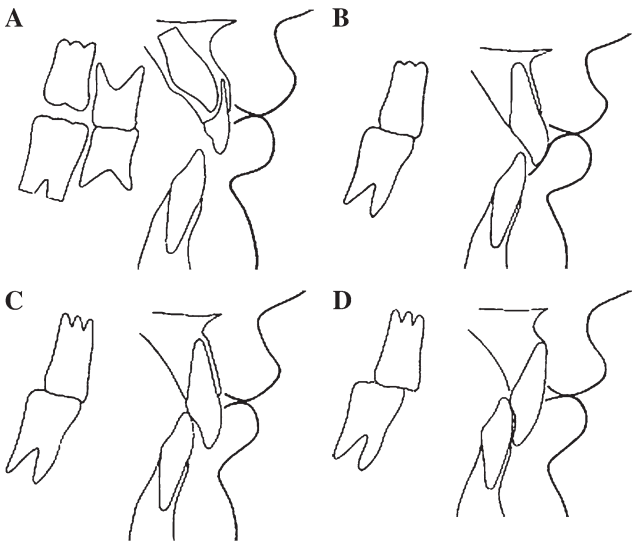


Figure 6 Normally, the deciduous incisors are inclined about perpendicular to the occlusal plane, also when a cover bite will develop. Only the complete covering of the maxillary deciduous incisors by the lower lip indicates that a cover bite will develop (A). Already prior to emergence, the inclination of the maxillary incisors starts to change. After emergence, excessive contact with the lower lip leads to their gradual tipping, and overeruption (B,C). The contact with the maxillary incisors results in lingual tipping of the mandibular incisors, and an increase of the deep bite (D).

Interpretation of Growth Data

Visual interpretation

In 1970, the author published two papers in the journal *Growth*. The first one “The interpretation of incremental data and growth curves” mainly dealt with the visual interpretation of graphical presentation of growth data (Van der Linden, 1970¹). In the traditional way of presentation by graphs, the recorded values are plotted and connected with each other. Incremental data are visualised by plotting half way between subsequent observations the addition that had been recorded by abstracting the previous observation from the following one (Figure 7). The problem with this way of presenting is that by looking at an incremental curve you gain the impression that the growth peak lasted longer than it actually did. Indeed, the ascending part of the peak is the connection between a point representing a relatively large change for the period that was preceded by a period of small change. However, for the descending part the reverse holds true.

A histogram is better suited for the illustration of incremental data of a single individual. The height of a bar represents the average rate during the time interval represented by its base. In the polygon presentation, formed by connecting points with straight line segments, the peak stretches over to the next period, in which only little growth occurred (Table 1, Figure 8).

The relationship between the timing of a certain biological phenomenon and the dates on which records are taken, can affect the information obtained considerably. Theoretically, a

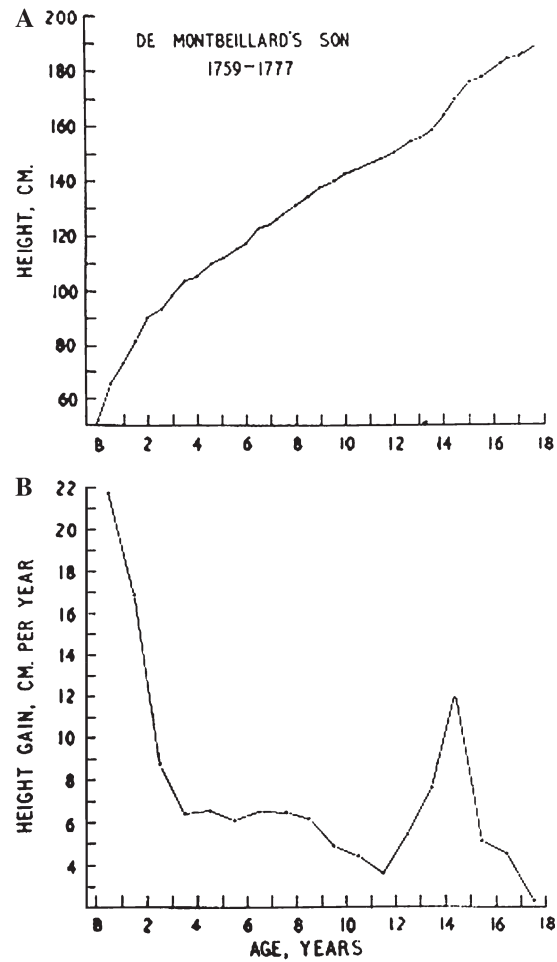


Figure 7 Growth in height of the son of the Count de Montbeillard, data collected from birth until the age of 18 years, 1759-1777 (Tanner 1962). Curve of the total height (distance curve) (A). Height increment curve, which sets out the amount by which the total height increased each year (velocity curve) (B).

Table 1

Hypothetical yearly increments						
Recorded age period	8-9	9-10	10-11	11-12	12-13	13-14
Units registered	5	4	5	12	5	4

growth spurt that lasts 12 months will be recorded as a one-year spurt only, when one of the annual measurements happens to coincide with its date of onset. When the registrations are planned six months later in time, then the one-year lasting growth spurt will be recorded as one that was equally spread over a two-year period. This phenomenon and some other aspects are illustrated in Figure 9. The here mentioned phenomena justify the statement that many biological events presented in incremental data, or in velocity curves, are probably of a shorter duration than is usually concluded.

It is well-known that the rapid increase in stature during puberty does not happen uniformly but occurs in a specific sequence in the various parts of the body. First the legs become longer and some time later the trunk increases in

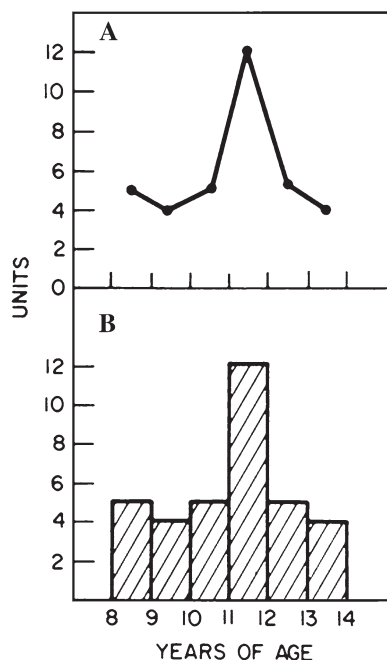


Figure 8 Recorded yearly increments of Table 1 are illustrated in a velocity curve, formed by connecting points with straight line segments (A). The same data presented in a histogram. Now it becomes clearer that the spurt was recorded over one year only (Van der Linden, 1970¹) (B).

height. Furthermore, the lower leg precedes the upper leg in the period of rapid growth (Figure 10). From these observations, in addition to the phenomena explained above, can be concluded that in separate anatomical structures, as long bones, the rapid proliferation of cartilage at the epiphysal disks can lead to a marked increase in bone length in a short period of time. The same holds probably true for the mandible in which the cartilage at the condyle also provides the potential of rapid growth.

Error of the method

The second paper in the journal Growth "On the analysis and presentation of longitudinally collected growth data" focuses on the mathematically and statistically correct interpretation of collected growth data (Van der Linden *et al.*, 1970²). In that respect, the error of the method is essential, which increases by $\sqrt{2} = 1.4$ in cases of adding or abstracting independent normally distributed variables (Figures 11A, B).

Two single, independent variables drawn from normal distributions can be considered to differ significantly with a confidence level of 95% when two recorded values are $2.8 (=1.96 \times \sqrt{2})$ or more times the error of the method apart (Figure 11C).

Neighbouring increments in longitudinal growth data have a negative correlation induced by the way they are obtained. They cannot be treated as independent variables (Figure 11). Consequently, differences between two single

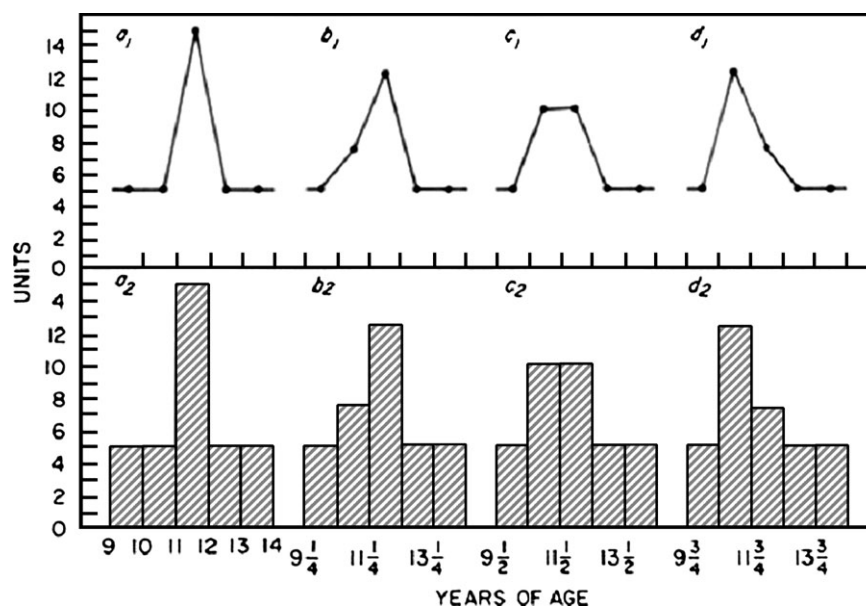


Figure 9 Theoretical model with a continuous increase of 5 units per year on which a growth spurt from 11 to 12 years, equally distributed over 12 months and of magnitude 15, is superimposed. a. The date of recording coincides with the onset of the spurt; the change in growth is registered over a one-year period. Illustrated as velocity curve (a₁) and presented in histogram form (a₂). b. The annual recordings moved up three months. c. *Idem* six months, the changes in growth are now registered as being equally spread over a two-year period. d. *Idem* nine months. Compare the differences in information as expressed for the four cases by the velocity curves and the histograms (Van der Linden, 1970¹).

neighbouring increments can only be considered as significant with a confidence level of 95% when the two recorded increments are $4.8 (= 1.96 \times \sqrt{6})$ or more times the error of the method apart (Figure 11D).

Reliability of cephalometric conclusions

The comments made above regarding the effect of the error of the method apply also to data collected from tracings of lateral roentgenocephalograms. For example, the angle

ANB is calculated as the difference between angle SNA and angle SNB. Accepting an average error of the method for all bony point determinations of 0.7 mm, and that corresponds with 0.7° for the angles SNA and SNB in the calculation of angle ANB, the error of the method for angle ANB will be $\sqrt{2} \times 0.7^\circ = \text{about } 1^\circ$. This implies that for arriving at the conclusion that the angle ANB has changed significantly at a 95% confidence level between the start and the conclusion of active treatment the difference should be at least 2.8° . To be able to conclude that the change in angle ANB between the start and the conclusion of active treatment is larger than the change in angle ANB between the latter and two years later the difference should be 4.8° or more.

Clinicians seldom realise these limitations. Over the years, many superimpositions of tracings have been made with the presumption to accurately visualise changes during treatment and thereafter. Also treatment results and subsequent changes have been quantified in tenths of mms and degrees. Examinations at the end of educational programs usually require documentation of treated cases including superimpositions with accompanying numerical data. The same applies to those who take the examination for the American Board of Orthodontics and boards in other countries. The author does not expect that the profession is readily willing to accept these limitations and realise the

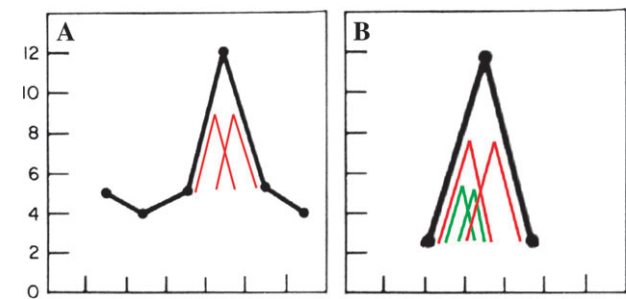


Figure 10 Theoretical model in which the growth spurts of the legs (left) and of the trunk (right) are drawn in colour green in the velocity curve of the total height (A). Within the growth spurt of the leg, the velocity curve of the lower leg (left) and the one in the upper leg (right) are drawn in colour red (B).

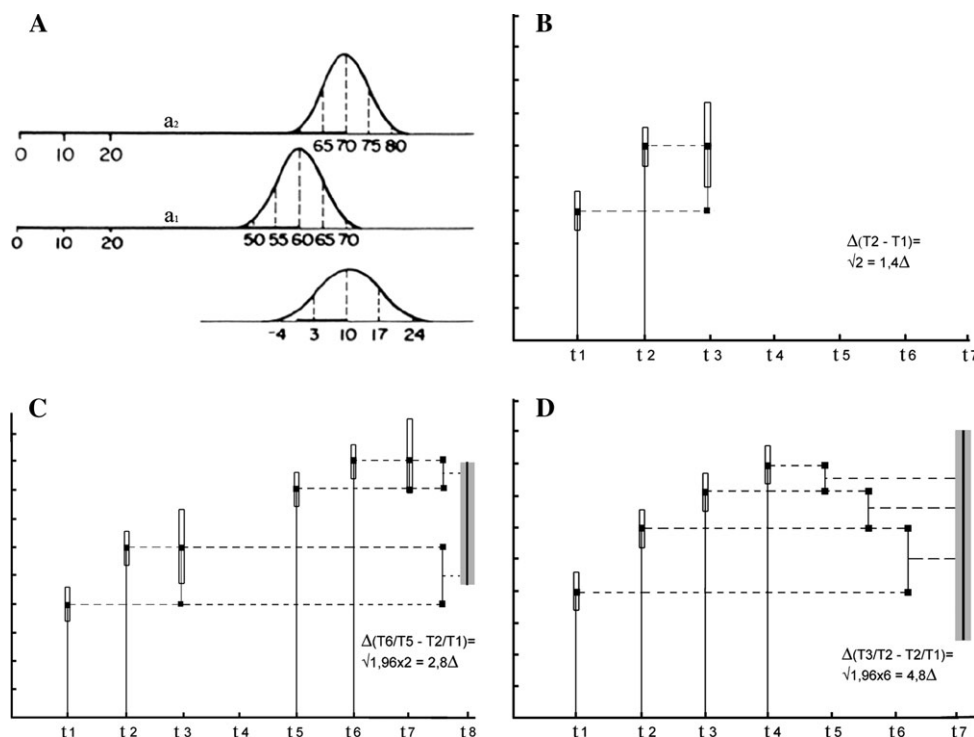


Figure 11 The error of the method (Δ) for the dimension a_1 and a_2 is assumed to be 5 mm. When both are independent of each other and normally distributed, the error of the method of their difference ($d=a_2-a_1$) is $\sqrt{2} \times 5 \text{ mm} = 7 \text{ mm}$ (according to the rule $V1+2=V1+V2$) (A). The error of the method for the difference between the recordings at t_2 and t_1 $\sqrt{2}\Delta = 1.4\Delta$ (B). The recorded difference in increments between two single independent variables (t_6-t_5 and t_2-t_1) has to be $(1.96 \times \sqrt{2})\Delta=2.8\Delta$ or more apart to be considered significant at a 95% confidence level (C). The recorded difference in single neighbouring increments (t_3-t_2 and t_2-t_1) or (t_4-t_3 and t_3-t_2) has to be $(1.96 \times \sqrt{6})\Delta=4.8\Delta$ or more apart to be considered significant at a 95% confidence level (D).

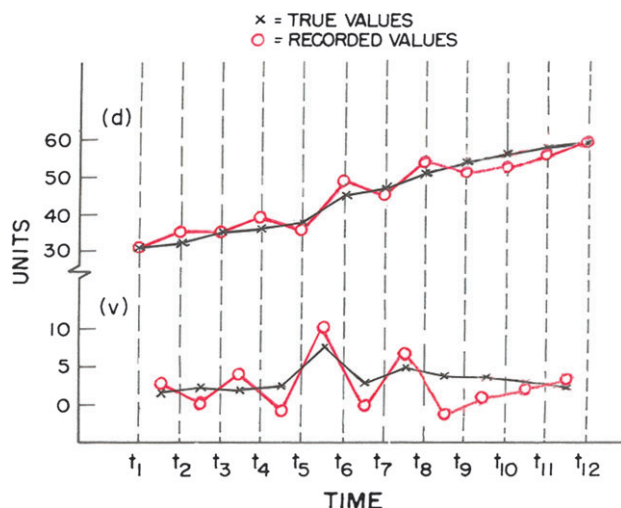


Figure 12 The effect of the error of the method on distance (d) and velocity curves (v). In the latter, the error influences consecutive measurements in the opposite way, resulting in an induced negative correlation between the members of pairs of increments. The change recorded from t_1 to t_2 is too large because the observation at t_2 erred to the large size. The reverse holds true for the recorded change from t_2 to t_3 . The same phenomena can be seen from t_3 to t_4 and t_4 to t_5 . The recorded change between t_6 and t_7 , and t_8 and t_9 , are too small due to the cumulative effect of the error in the recordings. The reverse is seen between t_5 and t_6 , and t_7 and t_8 . When two or three neighbouring values are recorded as too small (t_9 , t_{10} , t_{11}) or too large they compensate each other to some extent when the increments are calculated. Errors of the method can be cumulative and compensatory in the calculations of increments.

inaccuracy of tracings and superpositions. Nevertheless, the assumed accuracy is a myth.

How difficult it is to arrive at reliable conclusions in the analysis of longitudinal growth data was experienced in the Nymegen Growth Study, a mixed-longitudinal interdisciplinary study of growth and development that involved 468 children. Of all recorded cephalometric values, only a significant adolescent growth spurt could be concluded for the measurement articulare-gnathion in boys, but not in girls (Prah Andersen *et al.*, 1979).

In conclusion, the calculation and presentation of growth data contain pitfalls. Indeed, some mathematical and statistical knowledge is required to arrive at valuable conclusions. Most clinicians are not aware of these shortcomings and reach conclusions which are not substantiated by the information provided, particularly regarding cephalometric data.

Diagnostic procedures

Since the introduction of roentgencephalometrics in the early thirties of last century, various sophisticated techniques have been developed which provide detailed three-dimensional information of the head, in digitised form. There is a tendency to apply these techniques in instances where it is not needed. The information that is required to

arrive at an adequate diagnosis and treatment plan can often be obtained with simpler and cheaper means.

That also applies to lateral roentgenocephalograms which are routinely taken in orthodontic offices worldwide. However, they are frequently not needed. That view was expressed already more than 20 years ago as the quote taken from the textbook "Diagnosis and Treatment Planning in Dento-facial Orthopedics" shows (Van der Linden and Boersma, 1986).

"Nowadays, it is not necessary to take a lateral skull radiograph of the average patient who presents himself for orthodontic treatment. In fact, only a limited number of cases will actually need such a radiograph, i.e., patients with markedly abnormal faces and extreme anomalies and particularly those cases where disturbed facial growth seems evident, or may be expected, such as some Class II and Class III anomalies and cleft patients. If combined orthodontic and surgical correction is contemplated, then lateral and often other skull radiographs are indispensable. This also applies for anomalies with a marked component of asymmetry."

However, little has changed in that respect as could be expected as long as insurance companies are willing to pay for the radiographs and in addition offer a fee for making tracings and numerical quantifications: the cephalometric analysis. Also the requirements of these records and analyses for examinations and Boards make it difficult to abstain from collecting them.

The essential formation, that is required to arrive at an adequate diagnosis and treatment plan, can be obtained in most cases by careful examination and palpation of the patient, dental casts derived from high quality impressions and an orthopantomogram or complete set of intraoral radiographs. Important is a good estimation of the anteroposterior jaw relationship, the relative height of the lower face, and the dimensions of the part of the jaws which can contain the forming teeth and the roots of the occluding permanent teeth, in comparison to tooth dimensions. To facilitate the estimation of the relationship between the teeth and the jaws the author introduced the concept of the apical area, divided for each jaw in three sections, of which only the posterior ones increase substantially with growth (Figures 13–15). Of course, a good understanding of the development of the dentition and of facial growth is needed to be able to estimate what can be accomplished with treatment and expected during the remaining period of growth.

In conclusion, there is a tendency of clinicians to use radiographs and sophisticated techniques to arrive at a diagnosis which can be obtained with simpler and cheaper means. The influence of refunding by insurance companies and the add to the professional esteem should not be underestimated in this phenomenon.

Validity of Facial Orthopedics

Many practitioners who use headgears, facial masks and functional appliances believe that by using these methods

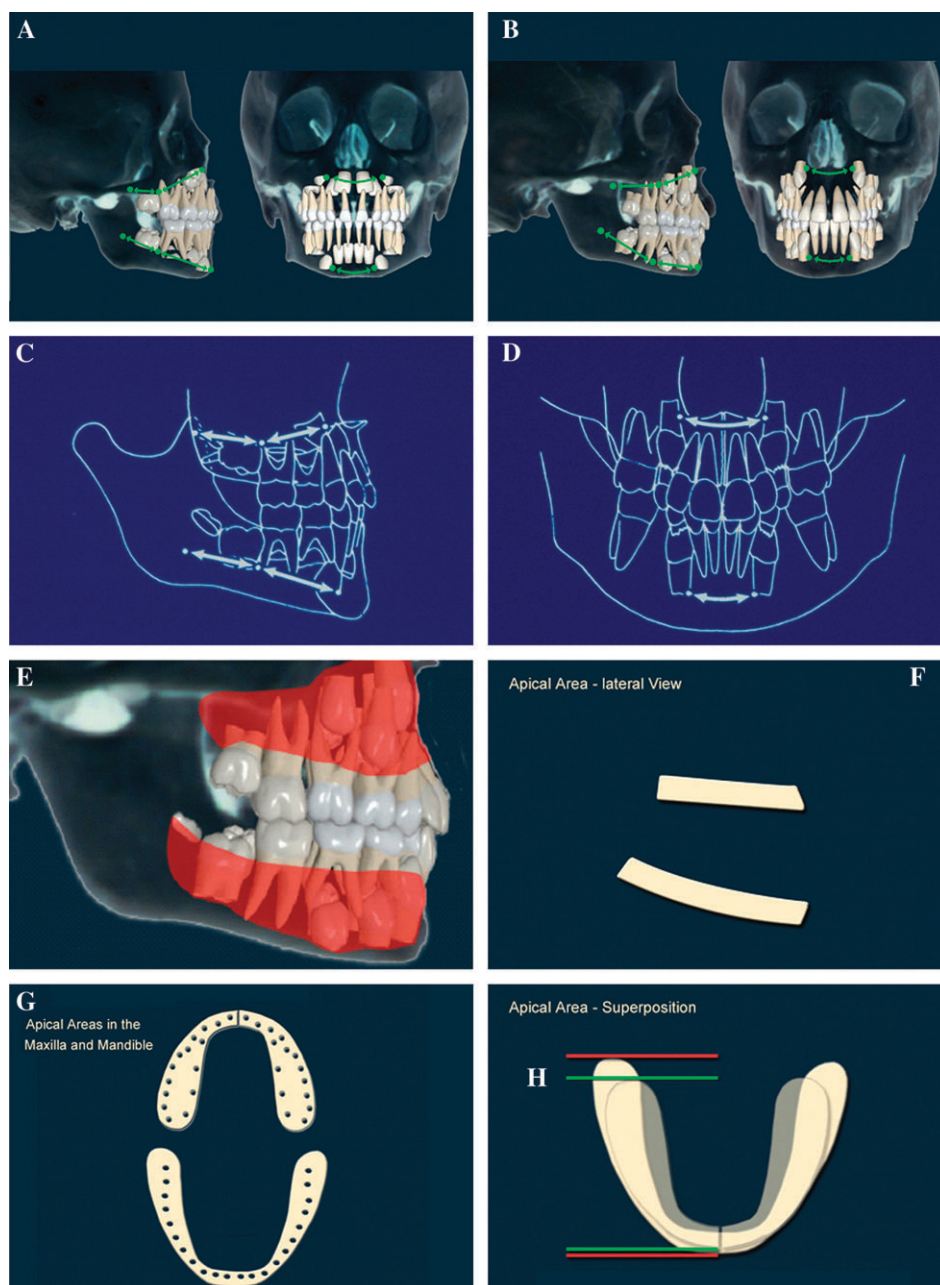


Figure 13 The apical area is the region in which the teeth are formed and in which the roots are located after emergence, they are shown for the deciduous (A) and for the mixed dentition (B). In both jaws the apical area can be divided in anterior, middle and posterior sections. The anterior section is the one between (the forming parts of) the apices of the canines, the middle section extends to the mesial side of (the forming part at the apex of) the first permanent molar, and the posterior section lies distally to it. They are shown for the deciduous dentition in lateral view (C) and for the mixed dentition in the anterior view (D). The apical area in the mandible extends more anteriorly and posteriorly than the one of the maxilla (E,F,G). That applies also in the lateral directions (G,H).

more beautiful faces can be created than otherwise should have come about. Also the author believed that until the findings of the randomized clinical trial from the University of North Carolina were presented (Tulloch *et al.*, 1998). These findings demonstrated a large variation in growth behaviour and response to facial orthopedic treatment.

Some children with Class II/1 malocclusions improved in sagittal jaw relationship during the observation period, even without any therapy. Some of the children who received treatment became worse. The demonstrated diversity in growth patterns and variation in treatment response altered the way the author looked at the effect of facial orthopedics.

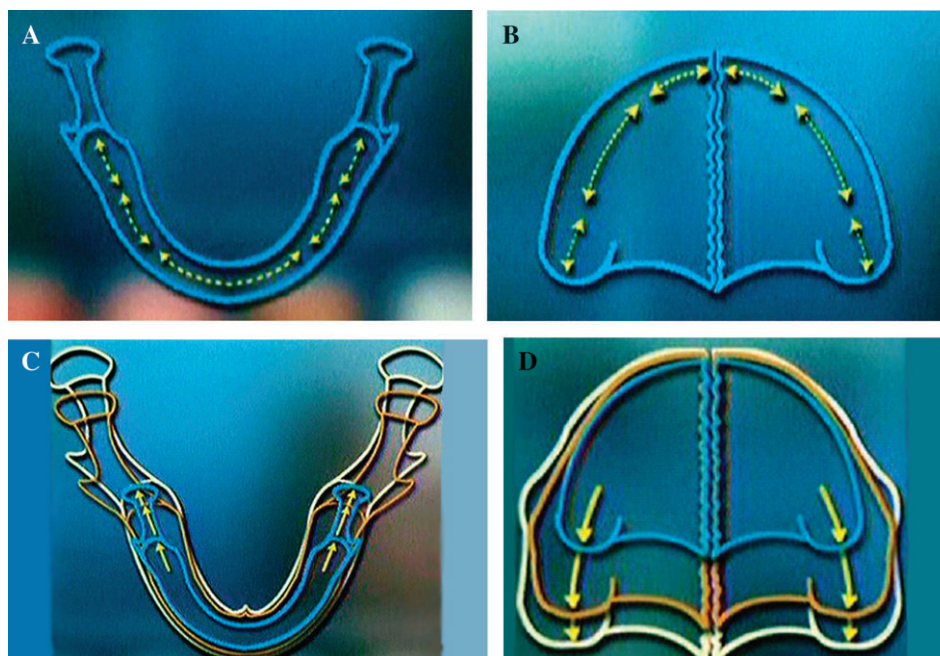


Figure 14 After the mandible has become ossified, the anterior section (where the symphysis is closed before the deciduous central incisors erupt) and the middle section do not increase in length anymore. Only the posterior section increases gradually with growth. However, by apposition of bone the buccolingual dimension of the mandibular body increases (A,C). In the maxilla the anterior section can increase in length until adulthood by means of apposition of bone at the midpalatal suture. In addition, the width of the maxilla can increase by apposition of bone at the buccal surfaces of the alveolar process. But, also in the maxilla most growth occurs to the posterior by lengthening of the posterior section (B,D).

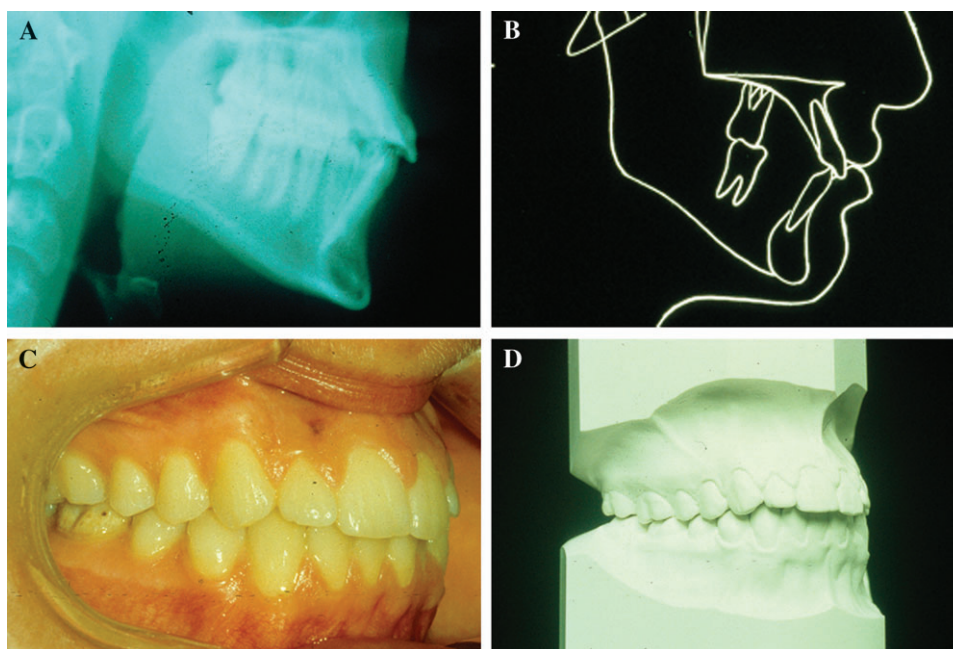


Figure 15 Records of a girl of 14 years of age. Parts of the lateral roentgenocephalogram (A) and tracing (B), intraoral photograph (C) and plaster model (D). The anteroposterior relationship of the anterior boundary of both jaws at the apical region of the central incisors can well be estimated at the patient and at the dental casts. That applies also to the size of the various sections of the apical areas, with exception of the posterior sections in the mandible.

A reappraisal of treated cases and particularly the girl he preferred to demonstrate the favourable effect of facial orthopedic therapy made clear that even she did not end up as a beautiful lady thanks to the therapy. Data collected two-and-a-half years before treatment started showed that with a favourable growth pattern the situation had improved already without any help. Furthermore, during the treatment, the facial configuration improved only slightly. The most pronounced improvement of the face occurred after treatment was concluded (Figure 16).

The tracings show that during treatment the height of the lower part of the face increased considerably with the increase in ramus length. This phenomenon has been found to occur with cervical headgear treatment (Baumrind *et al.*, 1981). A long-term study performed at the University of Nymegen again made clear that, in comparison to a control group, children treated with a cervical headgear experienced mandible growth in caudal direction with a substantial increase in ramus length. The study further revealed that in the two years following treatment, the mandible grew mainly anteriorly and very little in caudal direction. In the control group, such a dichotomy between vertical and sagittal growth was not observed. During treatment with the cervical headgear, the direction of facial growth was altered, but, with growth in the years following, the previous facial configuration returned (Figure 17).

Figure 18 presents a girl with a large lower anterior facial height, in whom a parietal (high-pull) headgear had restricted the caudal development. However, marked vertical development occurred after treatment. The total height of the face barely increased during treatment. The growth of the maxilla was inhibited, and the chin had moved anteriorly. The vertical development after treatment was considerable. The maxillary permanent first molars erupted significantly, the condyles experienced extensive vertical growth, and the lower facial height increased substantially.

It is often not realised, how much growth still can take place after active treatment has been concluded. To demonstrate that aspect, Bolton standards have been differentiated in periods of facial growth of three years (Figure 19). These illustrations show that the quantity of growth influenced by treatment is relatively small. It has been demonstrated that, after facial orthopedic treatment, the former growth pattern returns (Melsen, 1978). The effect is clearer in boys than in girls, because boys exhibit more growth after treatment. The end result of facial orthopedic therapy depends mainly on the amount of growth that occurs after treatment and on the application of facial orthopedic retentions (DeVincenzo, 1991; Junkin and Andria, 2002; Pancherz, 1997; Wieslander, 1993). These aspects are illustrated in Figures 20–22. The return to the original growth pattern, the “catch-up” phenomenon, has been observed in overall body growth in humans and animals. A child who experiences a long-lasting illness or is severely underfed will not grow. When the health and living

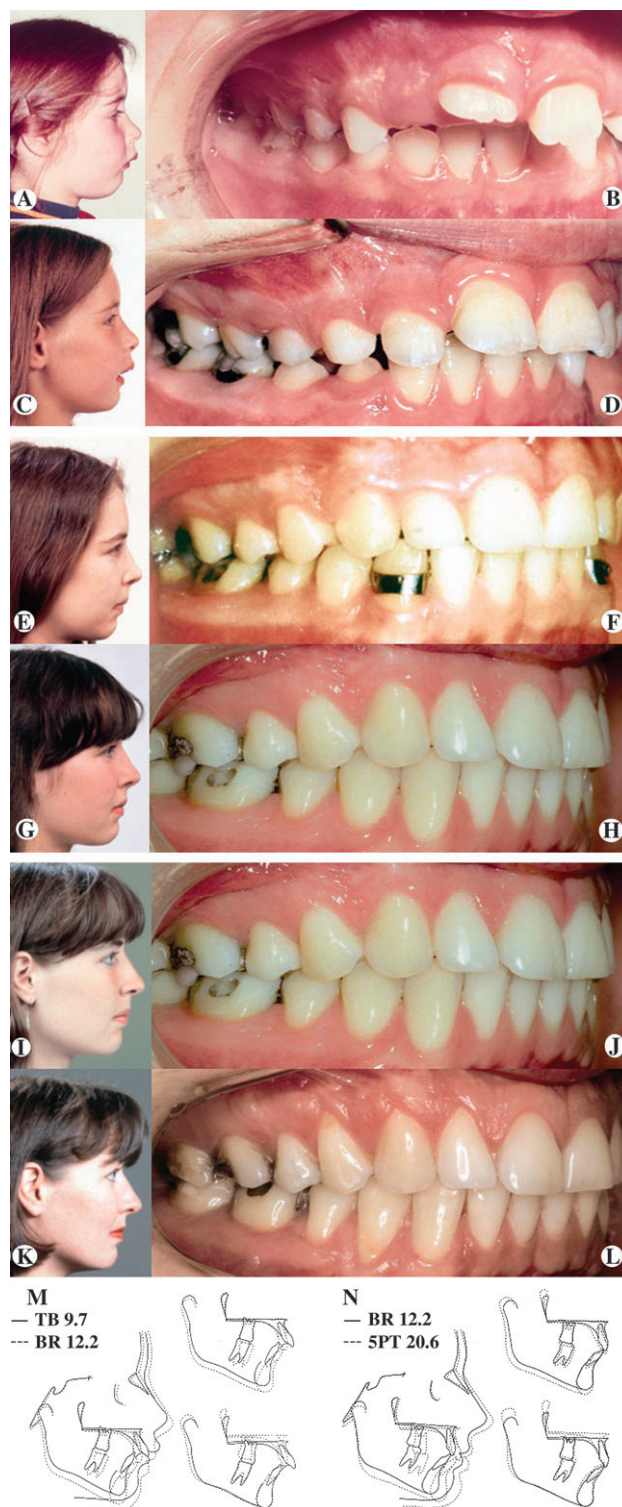

Figure 16 A girl aged 7 years, 2 months, had a severe Class II malocclusion (A,B). Without any therapy the facial profile and the malocclusion improved as documented at 9 years, 8 months, when treatment was started (C,D). First a cervical headgear was placed and full edgewise appliances were added ten months later. The treatment was concluded at 12 years, 2 months, of age (E,F). The mandibular retainer was removed at 15 years, 6 months, of age (G,H). Follow-up records were obtained at 25 (I,J) and 30 years of age (K,L). The overview of the lateral photographs and the superpositions of the tracings clearly demonstrate that the major improvements in facial configuration occurred before and after active treatment (M,N).

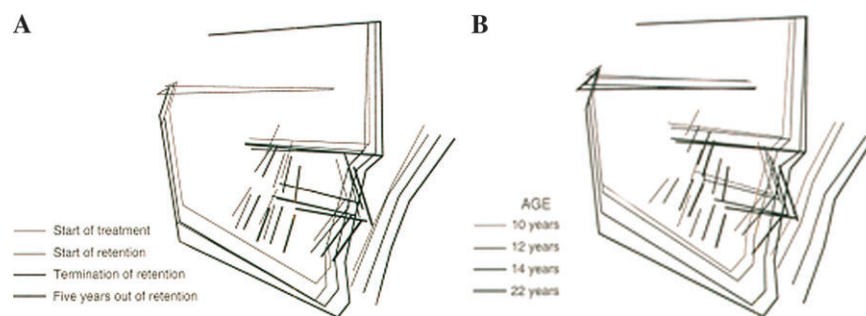


Figure 17 Changes in 26 boys with a Class II/1 malocclusion treated with a cervical headgear, usually with the addition of a maxillary plate (A) and 18 untreated boys from the “Nymegen Growth Study”(B). The records were collected at the beginning of treatment, the beginning of retention, the completion of retention and five years postretention. The records of the control group coincided in age. These changes were also found in the female samples of 24 experimental and 17 control girls. However, the changes and differences were less marked in girls than in boys (Hooijmaaijer *et al.*, 1989).

conditions have returned to normal, accelerated growth will compensate for the deficiency until the child is caught up. However, when poor conditions continue until the epiphyseal disks are closed, the potential stature will not be reached.

Although in general no permanent effect remains of facial orthopedic therapy that does not mean that such a treatment does not have advantages. Essential in that respect are the temporary improvement of the sagittal maxillomandibular relationship and the increase in lower facial height through which it becomes easier to reach a neutroocclusion in a biological way. When Class II/1 malocclusions are concluded with a rigid intercuspation, the neutroocclusion will be maintained (Figure 22A). However, that does not apply to Class III's, because continued mandibular growth can lead to mesioocclusion again. Besides, it is not clear if the changes caused by extraoral traction on the maxilla also experience the catch-up phenomenon. The long-term result of anterior traction exerted on the maxilla by a facial mask indicates that at least part of the effect is permanent.

In conclusion, the amount and direction of facial growth can be influenced to a limited extent by facial orthopedic therapy. However, with continuing growth after treatment and without facial orthopedic retention, the improvement in facial configuration by the treatment is lost, probably with the exception of the displacement of the maxilla. However, facial orthopedic therapy can still serve to facilitate the correction of Class II malocclusions at the end of the second transitional period.

Stability of mandibular incisor position

Irregularities of mandibular anterior teeth often occur after orthodontic treatment, even after years of retention. However, normal dentitions that never have been treated orthodontically show this phenomenon also, but less frequently (Sinclair, 1983).

The occurrence of irregularities in the mandibular anterior region has been blamed repeatedly on the return to the original intercanine distance after enlargement by orthodontic treatment (Sinclair, 1981; Little, 1999; Little *et al.*, 1990). However, a decrease of this distance has also been observed in normal occlusions at a later age (Meng *et al.*, 1985).

This generally for granted taken cause – effect relationship can also be turned around and it can be hypothesised as well that the occurrence of irregularities in incisor positions causes the reduction of the intercanine width. Indeed, irregularities of the mandibular anterior region can be attributed as much, or even better, to riding at the marginal ridges of the maxillary incisors (Duterloo, 1991; Van der Linden, 1998).

The morphology of the anterior teeth varies considerably. The shape of the palatal surfaces of the maxillary anterior teeth determines how extensive the occlusal contacts can be and where these contact can be located. Some maxillary incisors have heavy marginal ridges which extend to the incisal edge. Others may have ridges that do not reach so far and have a flat palatal area close to the incisal edge that allows full occlusal contact with a shallow overbite (Figure 23). However, the overbite increases gradually after orthodontic treatment (Al Yami *et al.*, 1999). By this deepening of the bite the broad occlusal contact can alter in a riding of the incisal labial edges of the mandibular anterior teeth on the marginal ridges of the opposing incisors. It may well be that this is the primary cause of the occurrence of irregularities in the mandibular region, in orthodontically treated individuals as well as in those who never had undergone orthodontic therapy. The decrease in intercanine distance is then the effect, not the cause of the development of crowding. Hence, the author has recommended removing the marginal ridges of the maxillary anterior teeth in the last stage of orthodontic treatment (Figure 24). An alternative is filling up the area between the marginal ridges with composite that might be indicated in situations where a more palatal position of the maxillary incisors is not desired.

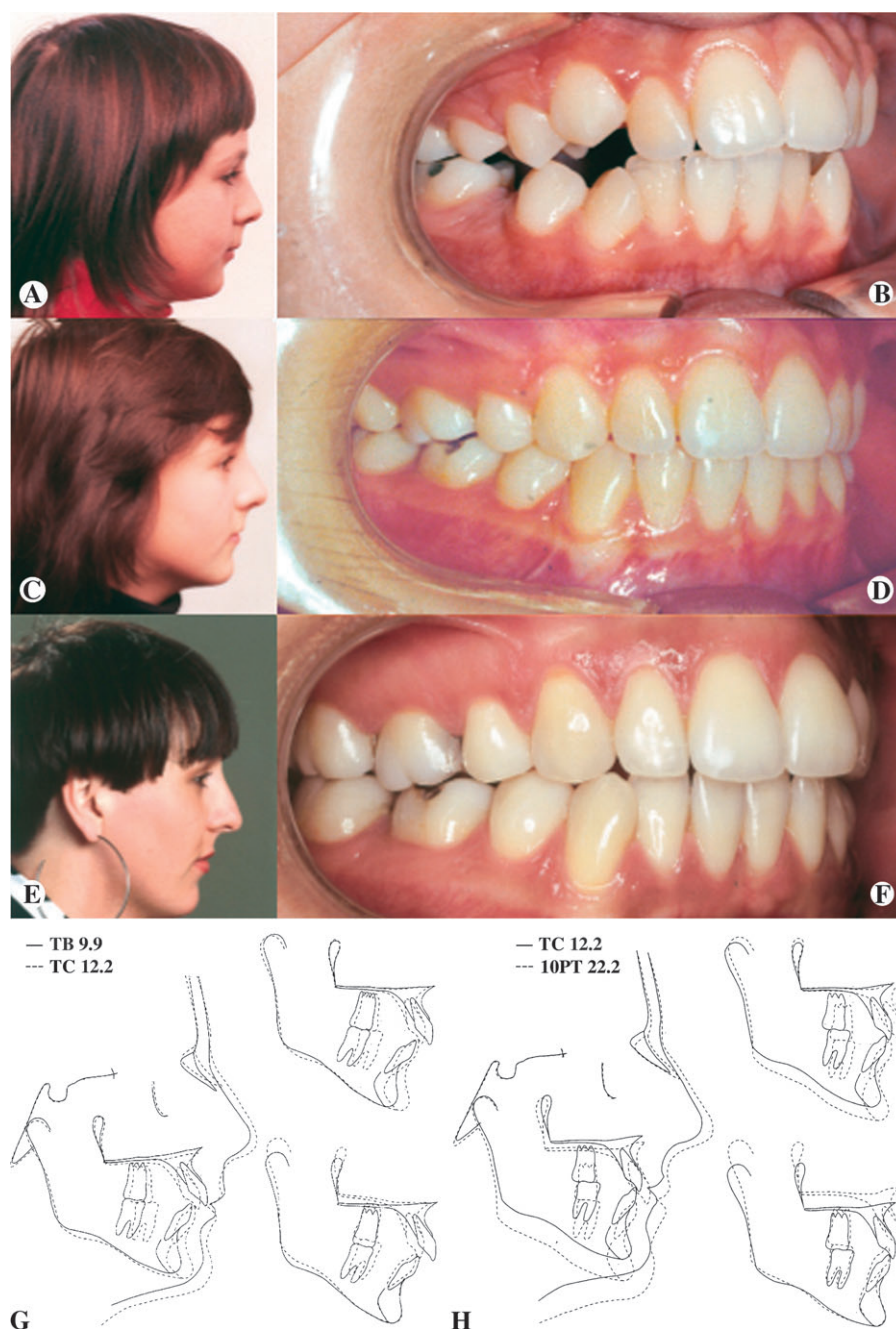

Figure 18 A girl aged 9 years, 9 months, had a class II/1 malocclusion with an anterior nonocclusion and extensive crowding in both dental arches (A,B). All four first premolars were extracted and a parietal (high pull) headgear and full edgewise appliances were used. After an active treatment of 1 year, 4 months, followed by a 6-months retention phase with a positioner, an ideal occlusion and a harmonious face were obtained (C,D). However, 1 year later the contact in the anterior region was lost, although the incisors still overlapped each other. Fifteen years later, at the age of 27 years, 11 months, the lower face had become markedly longer and an anterior nonocclusion was still present (E,F). The tracings and lateral photograph show that the direction and amount of facial growth were influenced effectively by the treatment (G). Thereafter, the former growth pattern was re-established because growth was not completed yet (H).

In conclusion, the idea that the increase of mandibular intercanine distance by orthodontic treatment is the cause of occurrence of irregularities in the mandibular anterior region, can be considered to be a myth. The removal of

marginal ridges of the maxillary anterior teeth is justified to arrive at flat occlusal contacts because it most likely will reduce the tendency to develop crowding in the mandibular anterior region.

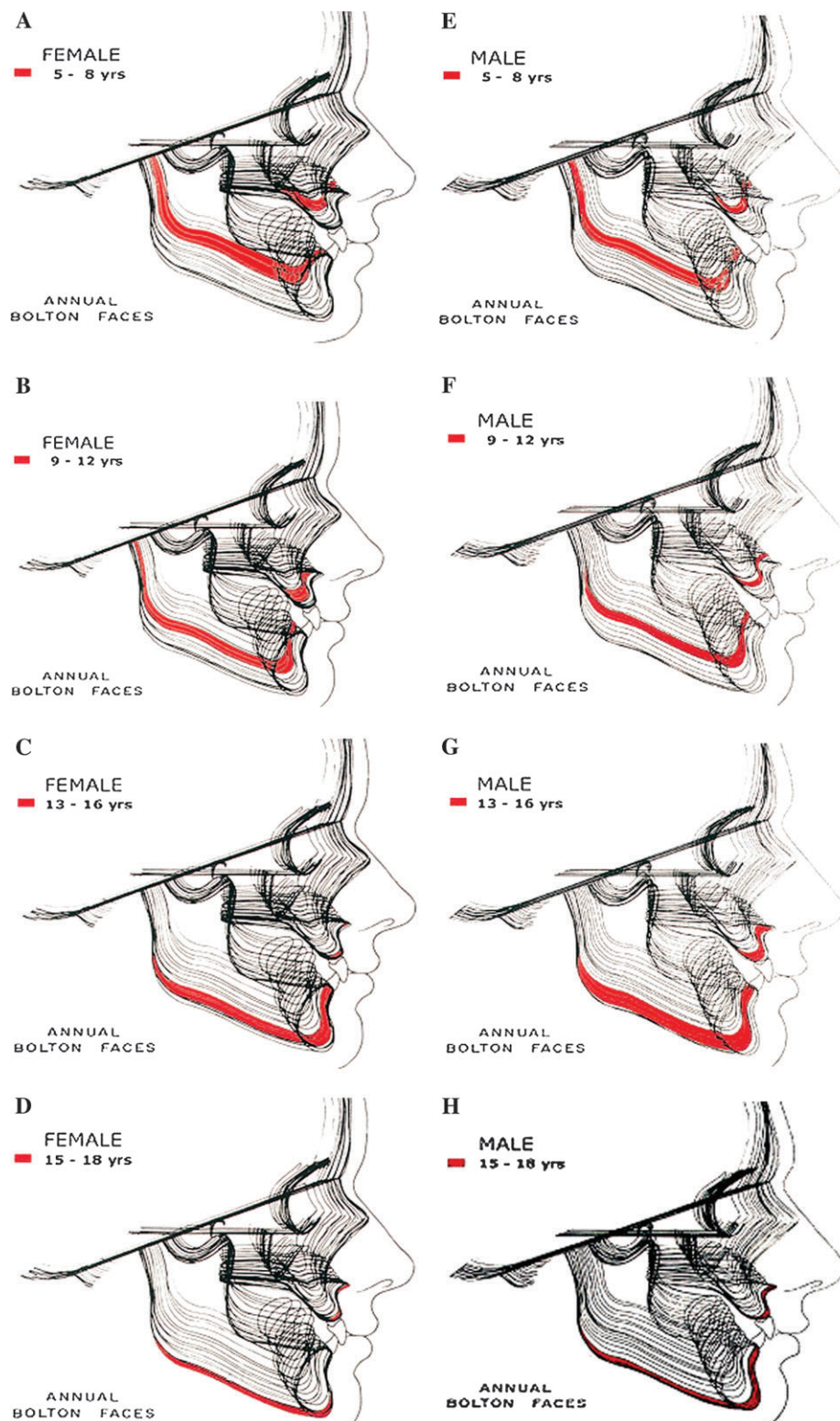


Figure 19 The Bolton Standards presented with coloring of areas representing three year periods of jaw growth. This is done to indicate the amount of growth, and the differences between various age periods between girls (left) and boys (right). Many treatments are carried out between nine and twelve years of age, during which girls experience the adolescent growth spurt (B,F). However, it is still questionable if the majority of girls truly undergo such a spurt in the face. Indeed, most boys experience a facial growth spurt that occurs at a later age (G). Of importance is also the amount of growth remaining after treatment, which is much more in boys than in girls. Overviewing these illustrations, it becomes clear that facial orthopedic therapy effects only a small part of the total facial growth in time. Considerable growth takes place before treatment, and also often thereafter. It is not realistic to assume a permanent effect of a facial orthopedic therapy when growth continues.

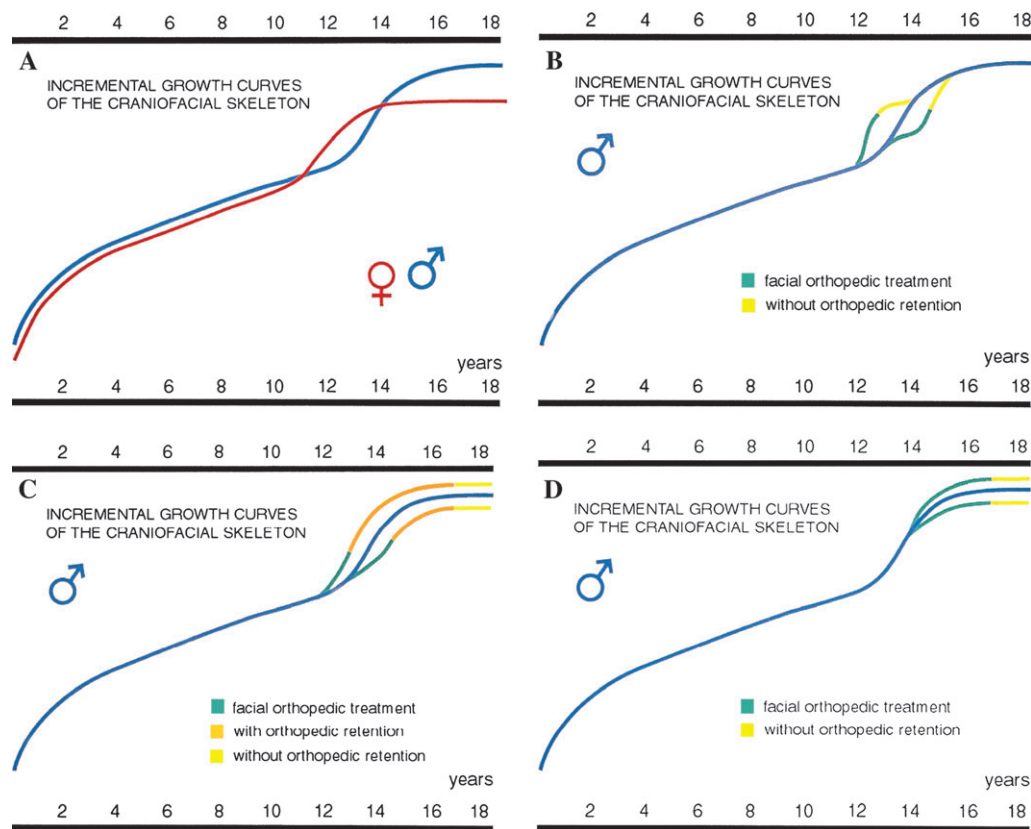


Figure 20 The assumed incremental growth curves of the craniofacial skeleton are presented in an exaggerated form for clarifying purpose. The facial growth spurt starts earlier, ends sooner and is of a smaller magnitude in girls than in boys (A). It is assumed that facial orthopedic therapy will increase or decrease the rate of growth of specific skeletal structures, resulting in a higher or lower course of the growth curve (green). After treatment decreased or increased compensatory growth takes place (yellow) and a return to the original growth curve occurs (B). When an active treatment is followed by a facial orthopedic retention period (orange) lasting until growth is completed, the effect of the treatment will be maintained probably to a large extent (C). The effect of the treatment will be maintained probably to a large extent also when treatment is carried out at the end of the growth phase (D).

Retention strategies

The introduction of bonding led to major changes in restorative dentistry, but also in orthodontics. Cementation of bands was replaced by bonding of attachments. Furthermore, the potential of improving the shape and colour of teeth contributed considerably to the attainment of beautiful looking dentitions, particularly when missing incisors are substituted by adjacent teeth.

It is remarkable that the introduction of bonding had little effect on retention strategies. By the moving from banding to bonding, interproximal spaces due to the presence of bands did not have to be closed anymore. Furthermore, all teeth could be brought to ideal positions because nothing interfered with interproximal and occlusal contacts. Consequently, there was no need anymore to move teeth with a retainer appliance after fixed appliances were removed when the treatment was carried out correctly. The traditional removable retainers, as the Hawley and “wrap-around” appliance do not offer adequate control over the canines as they have large open U-loops at the canine region

and the labial/buccal wires are flexible and can easily become deformed. Furthermore, when opposing posterior teeth are in correct mesiodistal and buccal relationships, they can sock-in after the appliance is removed. With normal functional conditions, the cone-funnel mechanism will lead to maximal intercuspation and the pressure of the tongue and buccal musculature will bring the posterior teeth to balanced positions. Indeed, retention of the posterior teeth is not needed in cases with a solid occlusion. Only the anterior teeth have to be supported three-dimensionally to maintain the positions obtained.

When it is accepted that teeth do not have to be moved with a retainer, the design has to meet the requirements of maximal control of the six anterior teeth with firm clasp functions in that area. In addition, the plate should be comfortable to wear and certainly biting on metal parts should be avoided. These conditions can be met with a 0.7 mm spring hard stainless steel wire that is fully in contact with the labial surfaces of all six anterior teeth. By returning the arch wire at the distal side of the labial surface of the canines to be continued in a C-clasp loop at the cervical

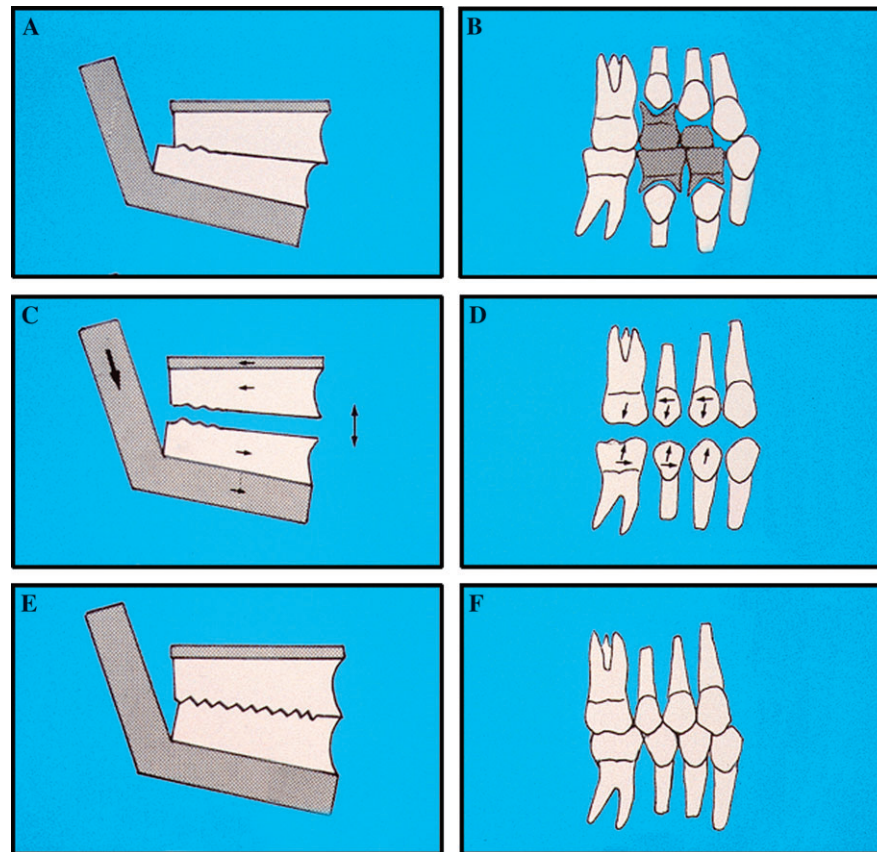


Figure 21 In the mixed dentition a rigid intercuspation does not exist because the occlusal surfaces of the deciduous molars have become flat through attrition, and the permanent first molars do not interdigitate (A,B). In an effective facial orthopedic therapy, the length of the ramus increases, the mandible attains a more anterior relationship to the maxilla, and the sagittal occlusion improves (C). Through the increase in lower face height, the erupting posterior teeth can be guided over a larger distance, facilitating directing them to the correct mesiodistal positions. In addition, emerging premolars are easier to direct when advantage is taken of the extra space that becomes available in the dental arches when their predecessors are shed (D). When the premolars and canines occlude with a rigid intercuspation after treatment, the realised improvement in occlusion of the posterior teeth will be maintained (E,F). Subsequent changes in the sagittal relationship between the two jaws will not affect the occlusion, because a partial or complete return to the original facial growth pattern will be accompanied by compensatory migration of teeth within the alveolar processes.

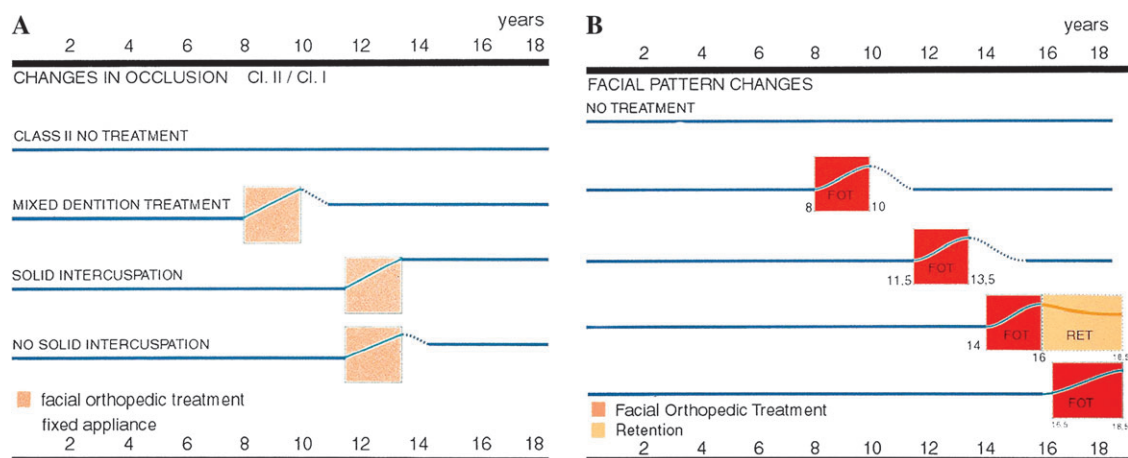


Figure 22 Changes in the occlusion of the posterior teeth will only be maintained if a rigid intercuspation exists. That is not the case in patients with occlusally flat deciduous molars or open bites and nonocclusions in the posterior regions (A). Changes in the facial configuration are not preserved when growth continues after treatment has been concluded (B).

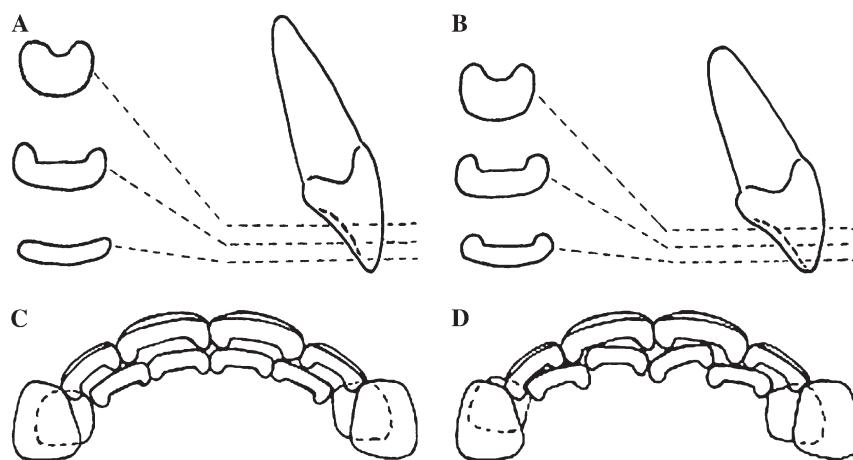


Figure 23 Maxillary incisors have marginal ridges. Mostly they do not reach to the incisal edge (A); but also quite often they do (B). Marginal ridges interfere with the establishment of broad, flat occlusal contacts in an ideal arrangement of mandibular and maxillary anterior teeth (C). Irregularly arranged mandibular incisors often have more occlusal contact (D).

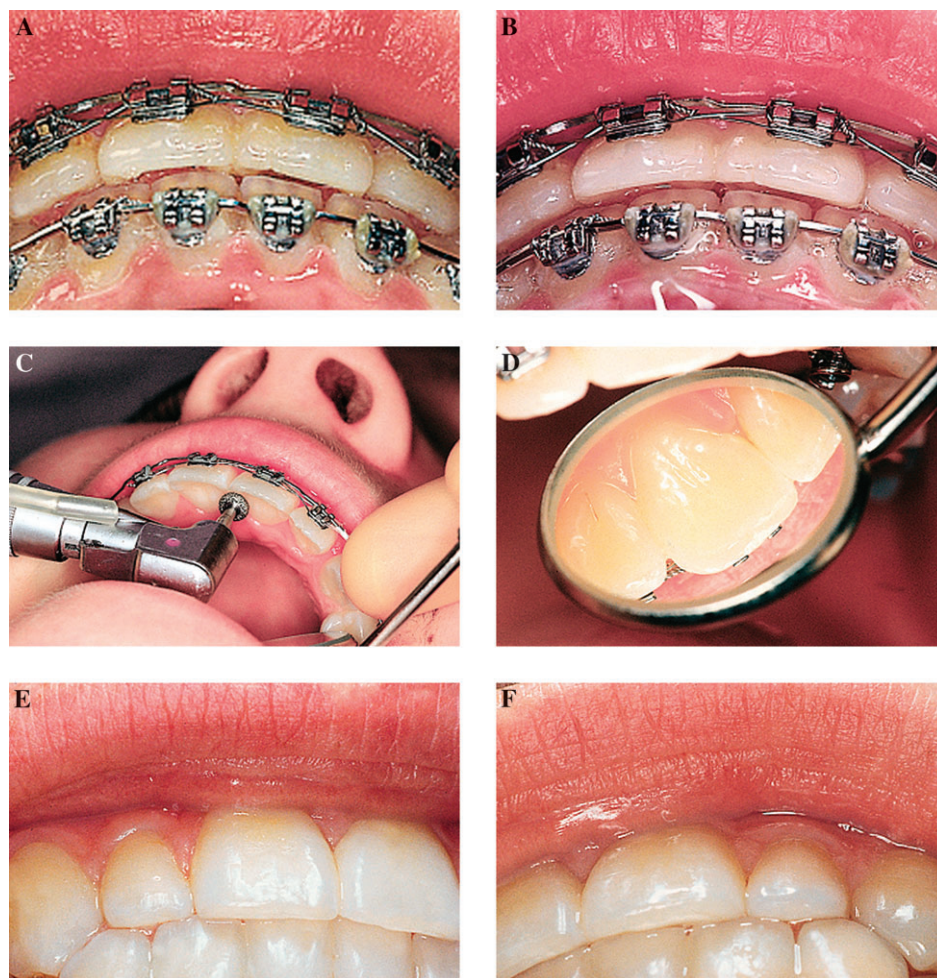


Figure 24 At the end of treatment, mandibular incisors were riding on the marginal ridges (A). The ridges were removed to create smooth, flat palatal surface (B). A wheel-shaped diamond stone used with excessive water cooling is a good tool for that purpose (C,D). The maxillary anterior teeth did not have to be reduced in width because the lateral incisors were relatively small. The removal of the ridges followed by the more palatal positioning of the maxillary incisor eliminated the existing Tooth Size Discrepancy (E,F).

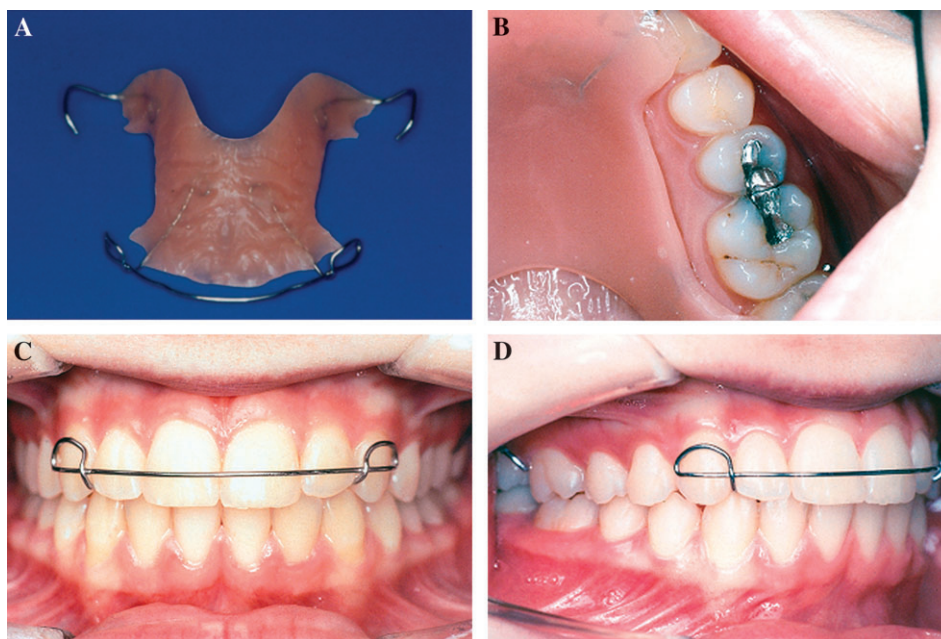


Figure 25 The Van der Linden retainer does not disturb the occlusion. Most lateral incisors have rounded distal corners, which allow palatal passage of the wire at a sufficiently high level (A,B). If not, there is usually enough space distal of the canines. The C-clasp then has to be placed at the adjacent premolar. The plate has to be kept thin, and the palate should be covered only partially (C,D) (Van der Linden, 2003).

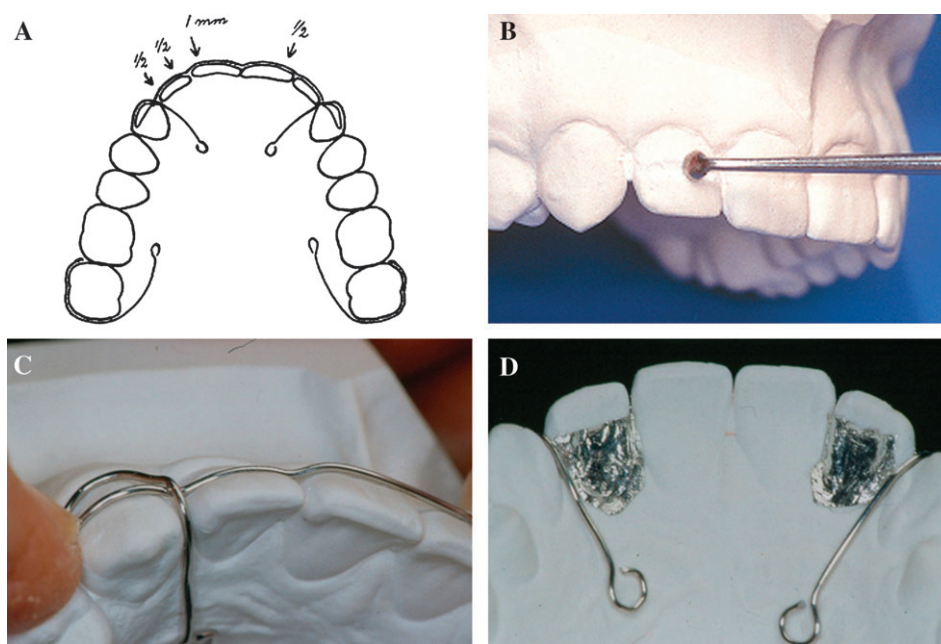


Figure 26 The desired instant corrections are indicated by the clinician in the design (A). Plaster is scrapped away where the labial arch has to be placed more palatally (B). The 0.7 mm spring hard stainless steel wire is bent so that it fits into the grooves (C). Layers of tin foil are closely adapted to the surfaces where the teeth have to move palatally. The thickness of the tin foil layers should be matched to the distance the tooth has to move palatally, so that the acrylic resin will solidly support the tooth when it has reached its destination (D).

area and subsequently going to the palatal between the canine and lateral incisor, rigidity, stability and fixation are secured. In case the technical skill is lacking to produce a well-adapted labial arch, application of a strip of clear

acrylic resin at the labial arch can provide adequate coverage of the labial contours. The palatal surfaces of the posterior teeth should not be in contact with the acrylic. These teeth should have freedom of movement to allow an unimpeded

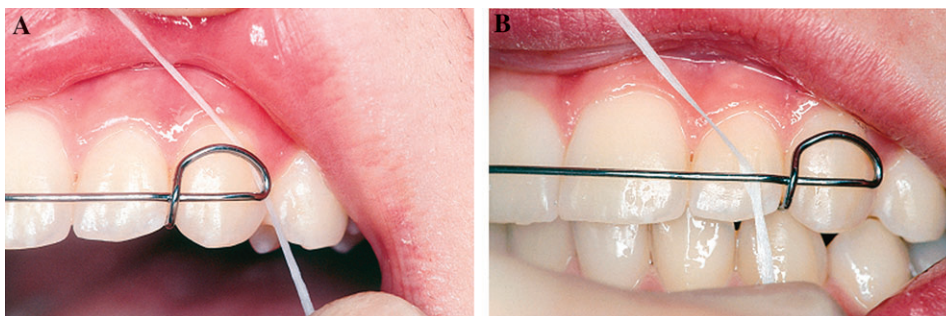


Figure 27 The clasp function at the canines and the adaptation of the contours of the labial wire to the labial surfaces can be controlled with silk dental floss.

socking-in and reaching balanced buccolingual positions. An exception applies to the most distally located molars which have C-clasps to add to the fixation of the plate (Figure 25).

Even after careful finishing of the treatment with multibracket appliances, minor irregularities can be overlooked which show up after the appliances are removed. These slight irregularities can be taken care of by “instant corrections” built in the retainer. Plaster is scrapped away where the labial arch has to be placed more palatally and layers of tinfoil closely are adapted to the palatal surfaces where the teeth have to move palatally. By modifying the plate for instant corrections, the teeth can attain the correct position right away. The extra wide periodontal spaces, present when the active appliances are removed, offers sufficient space to realise limited displacements instantaneously. Finally, the clasp function at the canines and the adaptation to the contours of the labial surfaces can be controlled with silk dental floss (Figure 27). The removable retainer described and recommended here can work excellent for many years, is rigid because it has no open loops and the labial wire does not deform with careful use. Checking once a year is usually sufficient when the patient handles the appliance diligently and removes it by pulling it down with fingernails on top of the wire at the cervical area of the canines.

Indeed, the widely used traditional removable retainers are not designed to be used after treatment with bonded fixed appliances. Retainers with flexible metal parts, intended to move teeth, should not be applied anymore, because only minor tooth movement should be required. Those can be handled well with instant correction.

Final remarks

Orthodontics can be differentiated in basic and clinical fields. In contrast to clinical approaches, basic aspects have altered little over the years. They have to be considered as the foundation of orthodontic theory. Lack of insight in the basic aspects leads to misinterpretation and improper

assumptions and procedures of which some have been presented above.

The basic aspects involve the “Development of the Dentition”, “Facial Growth and Facial Orthopedics” and “Orofacial Functions”. The author has been chief-editor of a series of DVD’s which treats these basic aspects in a sophisticated multimedia multilingual mode (Van der Linden *et al.*, 2003; 2004; 2002¹; 2002²; Van der Linden and Proffit, 2001; Proffit *et al.*, 2006). Furthermore, most of the topics presented here have been dealt with in detail in the author’s last book “Orthodontic Concepts and Strategies”, now available in six languages and from which most illustrations in this paper are taken (Van der Linden, 2004).

It has to be realised that the views presented above are the personal opinion of the author. He is the only one responsible for the contents of this paper.

Finally, it is appropriate to state that phenomena presented above are not unique for orthodontics. They occur in other dental disciplines, in medical fields and in other professions. Myths and legends are found everywhere.

Address for correspondence

Frans P.G.M. van der Linden
Pauluslaan 15
NL-6564 AP Heilig Landstichting
The Netherlands
E-mail address: fransvanderlinden@planet.nl

References

- Al Yami E A, Kuijpers-Jagtman A M, Van ‘t Hof M A 1999 Stability of orthodontic treatment outcome: follow-up until 20 years post retention. *American Journal Of Orthodontics and Dentofacial Orthopedics* 115: 300–304
- Baumrind S, Korn E L, Molthen R, West E W 1981 Changes in facial dimensions associated with the use of forces to retract the maxilla. *American Journal Of Orthodontics* 80: 17–30
- Björk A 1947 The face in profile. *Svensk Tandläkare-Tidskrift* Vol. 40: No. 5B, suppl. Berlingska Boktryckeriet, Lund
- Brodie A G 1944 Does scientific investigation support the extraction of teeth in orthodontic therapy. *American Journal Orthodontics And Oral Surgery* 30: 444–473

- De Kanter R J A M 1990 Prevalence and etiology of craniomandibular dysfunction. *Academisch Proefschrift, Katholieke Universiteit Nijmegen*
- DeVincenzo J P 1991 Changes in mandibular length before, during and after successful orthopedic correction of Class II malocclusions, using a functional appliance. *American Journal of Orthodontics And Dentofacial Orthopedics* 99: 241–257
- Downs W B 1952 The role of cephalometrics in orthodontic case analysis and diagnosis. *American Journal of Orthodontics* 38: 162–172
- Duterloo H S 1991. Development of the Dentition under Influence of Functional Factors. In: Hunter W S, Carlson D S (eds). *Essays in Honor of Robert E. Moyers. Craniofacial Growth Series, Vol. 24*. Pg. 103–122. Center for Human Growth and Development, The University of Michigan, Ann Arbor, U.S.A
- Frankenmolen F W A 1990 Orale gezondheid en zelfzorg van Nederlandse adolescenten. *Academisch Proefschrift, Katholieke Universiteit Nijmegen*
- Goldstein M S, Stanton F L 1936 Various types of occlusion and amounts of overbite in normal and abnormal occlusion between two and twelve years. *International Journal of Orthodontics* 22: 549–569
- Helm S 1970 Prevalence of malocclusion in relation to development of the dentition. *Acta Odontologica Scandinavica* 28: Suppl. 58
- Hooijmaaijer J, Van der Linden F P G M, Boersma H 1989 Post treatment facial development in corrected class II division 1-anomalies. *Journal of Dental Research* 68: 632
- Junkin J B, Andria L M 2002 Comparative long term post-treatment changes in hyperdivergent Class II division 1 patients with early cervical traction treatment. *Angle Orthodontist* 72: 5–14
- Little R M 1999 Stability and relapse of mandibular anterior alignment: University of Washington Studies. *Semin Orthodontics* 5: 191–204
- Little R M, Riedel R A, Stein A 1990 Mandibular arch length increase during the mixed dentition: postretention evaluation of stability and relapse. *American Journal Of Orthodontics Dentofacial Orthopedics* 97: 393–404
- Little R M, Wallen T R, Riedel R A 1981 Stability and relapse of mandibular anterior alignment – first premolar extraction cases treated by traditional edgewise orthodontics. *American Journal Of Orthodontics* 80: 349–365
- Melsen B 1978 Effects of cervical anchorage during and after treatment: An implant study. *American Journal Of Orthodontics* 73: 526–540
- Meng H P, Gebaurer U, Ingervall B 1985 Die Entwicklung des tertiären Engstandes der unteren Incisiven im Zusammenhang mit Veränderungen der Zahnbögen und des Gesichtsschädels bei Individuen mit guter Okklusion von der Pubertät bis zu Erwachsenen Alter. *Schweizer Monatschrift für Zahnmedizin* 95: 762–777
- Moyers R E 1988 *Handbook of Orthodontics*. 4th ed. Year Book Medical Publishing Inc., Chicago
- Pancherz H 1997 The effects, limitations and long-term dentofacial adaptations to treatment with the Herbst appliance. *Semin Orthodontics* 3: 232–243
- Prahl-Andersen B, Kowalski C W, Heydendaal P H J eds 1979 *A Mixed-Longitudinal, Interdisciplinary Study of Growth and Development*. Academic Press, New York.
- Proffit W R, Van der Linden F P G M, McNamara Jr J A, Radlanski R J, Pancherz H 2006 *Facial Growth, Dentition and Function. Dynamics of Orthodontics. Vol. 5 (DVD Series): Quintessence, Chicago*
- Sinclair P M 1983 Maturation of untreated normal occlusions. *American Journal of Orthodontics* 83: 114–123
- Tanner J M 1962 *Growth at adolescence*. 2nd ed. Blackwell Scientific Publications, Oxford.
- Tanner J M, Whitehouse R H, Marubini E, Resele L E 1976 The adolescent growth spurt of boys and girls of the Harpenden growth study. *Annals of Human Biology* 3: 109–126
- Tulloch J C, Phillips C, Proffit W R 1998 Benefit of early Class II treatment: Progress report of a two-phase randomized clinical trial. *American Journal Orthodontics and Dentofacial Orthopedics* 113: 62–72
- Van der Linden F P G M 1969 The application of removable orthodontic appliances in multiband techniques. *Angle Orthodontist* 39: 114–117
- Van der Linden F P G M 1970 ¹ The interpretation of incremental data and velocity growth curves. *Growth* 34: 221–224
- Van der Linden F P G M 1970 ² On the analysis and presentation of longitudinally collected growth data. *Growth* 34: 385–400
- Van der Linden F P G M 1971 ¹ A study of röntgencephalometric bony landmarks. *American Journal of Orthodontics* 59: 111–125
- Van der Linden F P G M 1971 ² The removable orthodontic appliance. *American Journal of Orthodontics* 59: 376–385
- Van der Linden F P G M 1983 Development of the dentition. Quintessence Publishing Company Incorporated, Chicago
- Van der Linden F P G M 1986 Facial growth and facial orthopaedics. Quintessence Publishing Company Incorporated, Chicago
- Van der Linden F P G M 1990 Problems and procedures in dentofacial orthopedics. Quintessence Publishing Company Incorporated, Chicago
- Van der Linden F P G M 1996 Practical dentofacial orthopedics. Quintessence Publishing Company Incorporated, Chicago
- Van der Linden F P G M 1997 Orthodontics with fixed appliances Quintessence Publishing Company Incorporated, Chicago
- Van der Linden F P G M 1998 The future of orthodontics: overview and discussion. In: Carels C, Willems G (Eds.) *The future of orthodontics*. Pg. 273–281. Leuven University Press, Leuven, Belgium.
- Van der Linden F P G M 2003 The Van der Linden retainer. *Journal of Clinical Orthodontics* 37: 260–267
- Van der Linden F P G M 2004 Orthodontic concepts and strategies. Quintessence Publishing Company Incorporated, Chicago
- Van der Linden F P G M, Boersma H 1987 Diagnosis and treatment planning in orthodontics. Quintessence Publishing Company Incorporated, Chicago
- Van der Linden F P G M, Duterloo H S 1976 Development of the human dentition. *An Atlas*. Harper & Row Publishers, Hagerstown
- Van der Linden F P G M, McNamara Jr J A, Pancherz H, Proffit W R 2004 *Facial Orthopedics. Dynamics of Orthodontics. Vol. 2b (DVD Series): Quintessence, Chicago*
- Van der Linden F P G M, McNamara Jr J A, Radlanski R J 2003 *Facial Growth. Dynamics of Orthodontics. Vol. 2a (DVD Series): Quintessence, Chicago*
- Van der Linden F P G M, Proffit W R 2001 *Orofacial Functions. Dynamics of Orthodontics. Vol. 4 (DVD Series): Quintessence, Chicago*
- Van der Linden F P G M, Radlanski R J, McNamara Jr J A 2000 ¹ Normal Development of the Dentition. *Dynamics of Orthodontics. Vol. 3a (DVD Series): Quintessence, Chicago*
- Van der Linden F P G M, Radlanski R J, McNamara Jr J A 2000 ² Malocclusions and Interventions. *Dynamics of Orthodontics. Vol. 3b (DVD Series): Quintessence, Chicago*
- Wieslander L 1993 Long-term effects of treatment with headgear – Herbst appliance in the early mixed dentition. Stability or relapse? *American Journal Orthodontics and Dentofacial Orthopedics* 104: 319–329